

Recurrent Patella Dislocations: Our Experience on the Outcomes of Non-Operative Treatment and Operative Treatments with Screw Fixation of Vastus Medialis Obliquus Tendon

Nuradeen Altine Aliyu¹ , Anipole Olalekan Akeem²

¹Department of Orthopedics and Trauma, Usmanu Dan Fodio University Teaching Hospital, Sokoto, Nigeria
Email: nuralast@yahoo.co.uk,

²Department of Orthopaedics and Trauma, Federal University Teaching Hospital, Birnin Kebbi, Nigeria.
Email: anipoleola@gmail.com

*Corresponding author: Nuradeen Altine Aliyu; nuralast@yahoo.co.uk

Received: 2 Aug 2024;

Revised: 9 Aug 2024;

Accepted: 20 Aug 2024;

Published: 26 Aug 2024

Abstract

Introduction: Patellar dislocation is a common acute knee disorders occurring mostly in children and adolescents. The management option can be non-operative or operative with many surgical techniques available based on the patho-anatomy of the disorder. There is challenge in the management in patients with generalized ligament laxity and other anatomical abnormalities. The aim of the study is to report the outcome of 17 patients with recurrent patella dislocation treated conservatively and surgically through the medial patella-femoral ligament (MPFL) repair and anchoring screw fixation to distal femur. **Methodology:** This is a retrospective study of 17 patients treated for recurrent lateral patella dislocations at Orthopaedic Hospital Wamakko, Sokoto, Nigeria between October 2016 and April 2022. Patients who met the inclusion criteria were fully evaluated and treated either conservatively or surgically. **Results:** The average follow up period was 2.2 years (range 2 to 3.2 years). The average presentation time was 6.5 Months (range 1 to 12 Months), and the average age at presentation was 24 years (range 16 to 34 years). There were 7 males and 10 females; the affected right knees were 7, and for the left knees were 8 with 2 bilateral knees affected. For the atraumatic patella dislocation group (n=10), the average Beighton score was 6 (range 2 to 9), and the Q angle, the trochlear morphology and the Caton-Deschamps index were all normal. Among the 17 patients in the study, 12 were treated conservatively, and 5 were treated operatively by plication of the medial patello-femoral ligament (MPFL) with subsequent screw fixation of the Vastus medialis obliquus (VMO) tendon to the distal femur. The average preoperative and postoperative Kujala scores were 68/100 and 94/100 points respectively, and that of Lysholm scores were 72/100 and 96/100 points respectively. **Conclusion:** Both conservative and surgical management for recurrent patella dislocation can offer satisfactory outcomes if patients were appropriately selected. In patients with generalised ligamentous laxity, MPFL plication repair with VMO screw anchorage to the femur can be a key to a successful and a desirable long-term treatment outcome.

Keywords: Recurrent patella dislocation, medial patellofemoral ligament, Vastus medialis obliquus, screw fixation

Introduction

Patellar dislocation occurs commonly in children and adolescents, and is one of the most common acute knee disorders [1,2]. The peak age of occurrence is usually at 15 years with the incidence of dislocations in the paediatric patients at about 43 per 100,000 [3]. When patella dislocations occurred, it can further results in other morbidities such as recurrent dislocations or instabilities, and long-term disabling patello-femoral osteoarthritis [4,5]. Experience of frequent episodes of affected knee “giving way”, reduced knee range of motion, swelling, and altered functional capacity are the common clinical presentation [6]. The aetiology of recurrent patellar dislocation (RPD) is multifactorial and ranges from trauma, to

generalised ligament laxity, and anatomical abnormalities predisposing to patellar instability such as trochlea hypoplasia, hypoplastic patella, genu recurvatum, deficient lateral femoral condyle, increased Q angle, patellar alta, and excessive femoral anteversion [7,8]. The affected young patients are often physically unfit to interact with their peers resulting in social isolation and reduced coping mechanism and other long-term psychological consequences [9]. Various treatment options, both operative and non-operative management have been used to treat patients with recurrent patella instability [10,11]. Although, non-operative treatment has been considered the standard treatment in the past [12], the current trend has been a recommendation for surgical treatment depending on the severity of the recurrent patella

instability, and in patients with failed conservative treatment or associated osteochondral fractures with loose bodies [13]. Many surgical techniques have been designed to correct the recurrent patella dislocations [14]. There have been varying surgical outcomes of these procedures, and no single technique is perfect for the complexity associated with the recurrent patella dislocations [15]. For the recurrent patella resulting from trauma, the lesion is usually straight forward even following attempted conservative treatment. The challenge lies more on the treatment methods for the recurrent dislocations associated with generalized ligament laxity and other anatomical abnormalities [16].

The aim of the study is to report the outcome of conservative treatment of 12 patients and operative treatment of 5 patients with recurrent lateral patella dislocation through medial patellofemoral ligament (MPFL) repair and screw fixation of Vastus Medialis Obliquus (VMO) tendon.

Methodology

This is a retrospective study of 17 patients treated for recurrent lateral patella dislocations at Orthopaedic Hospital Wamakko, Sokoto, Nigeria between October 2016 and April 2022. Following ethical approval (Ref no. SMH/1580/V.IV) before the commencement of the study, relevant data was obtained from the patients’ record and on follow-up at the outpatient department. The inclusion criteria were patient of any age with recurrent patella dislocation either resulting from trauma or ligament laxity. The exclusion criteria were recurrent patella dislocation with associated

knee ligament or meniscal injury that requires additional repair or reconstruction, presence of knee infection or congenital knee dysplastic changes, severe knee arthritis, and acute presentation of patella dislocation. All patients who met the inclusion criteria were further evaluated to ascertain the cause and suitability of treatment options. Thorough history and physical examinations were carried out, and patients were individually selected for initial conservative treatment before operative treatment option was considered based on response to the former treatment. History of recurrent episodes of lateral patella dislocations, the frequency of dislocation, time of dislocation, association with activities like sports, presence of knee pain, swelling, and stiffness, history of trauma and family history of RPD were all taken into consideration. Assessment of generalized ligamentous laxity using Beighton score [17] was done on patients with atraumatic patella dislocations (Figure 1a & 1b). The patient’s height, weight, and presence or absence of limb deformity, patella dimension, mobility, tenderness and whether it was displaceable in both full extension and at 30° of flexion were all noted. The Q angle was measured (figure 1c) and knee ROM assessed.

The radiograph was requested for to assess the trochlear morphology (groove and depth) (Figure 2b), the Caton-Deschamps index [18], and any degenerative changes (Figure 2a). The preoperative Kujala et al. score [19] and Lysholm score [20] were also assessed on every patient. The cardiovascular and other systemic examinations were carried out for further patients evaluation and general condition.

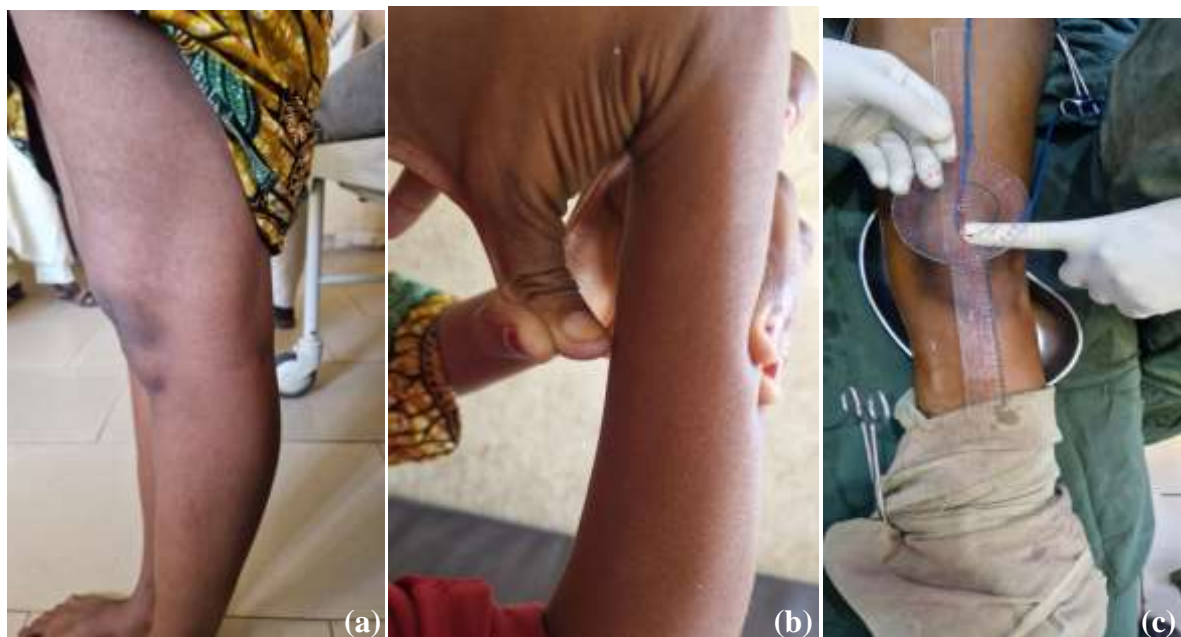

Figure 1: Assessment of generalised ligament laxity in a 27 year old female patient (Figure 1a & 1b); Measurement of Q Angle (Figure 1c).

Table 1: Demography of patients’ data treated for recurrent patella dislocation

Patient	Sex	Age (yrs)	Presentation history	Symptom duration	Side laxity	Ligament	Treatment Mo	Outcome (at 1 year)	Outcome (at 2 years)
1	F	18	No trauma	7 Months	Right	+	Conservative	Treated	Treated
2	M	21	Trauma	3 Month	Right	-	Conservative	Treated	LFU
3	F	16	No trauma	4 Months	Bilateral	+	Conservative	Treated	Treated
4	F	19	Trauma	6 Months	Left	-	Conservative	Reccured	Treated
5	M	22	No trauma	10 Months	Right	+	Operative	Treated	Treated
6	F	25	No trauma	8 Months	Left	-	Conservative	Treated	Treated
7	M	32	Trauma	6 Months	Right	-	Conservative	Treated	Treated
8	F	27	Trauma	5 Month	Left	-	Conservative	Treated	Treated

9	M	24	Trauma	1 Months	Left	-	Conservative	Treated	LFU
10	F	20	No trauma	5 Months	Bilateral	+	Conservative	Treated	Treated
11	M	31	Trauma	6 Months	Right	-	Conservative	Treated	Treated
12	F	27	No trauma	10 Months	Left	+	Operative	Treated	LFU
13	F	24	No trauma	12 Months	Left	+	Operative	Treated	Recurred
14	M	17	No trauma	1 Month	Left	+	Conservative	Treated	Treated
15	M	34	Trauma	5 Months	Right	-	Operative	Treated	LFU
16	F	21	No trauma	4 Months	Left	+	Operative	Treated	Treated
17	F	30	No trauma	8 weeks	Right	-	Conservative	Treated	LFU

yrs=years, +=present, -=absent, LFU=lost to follow-up

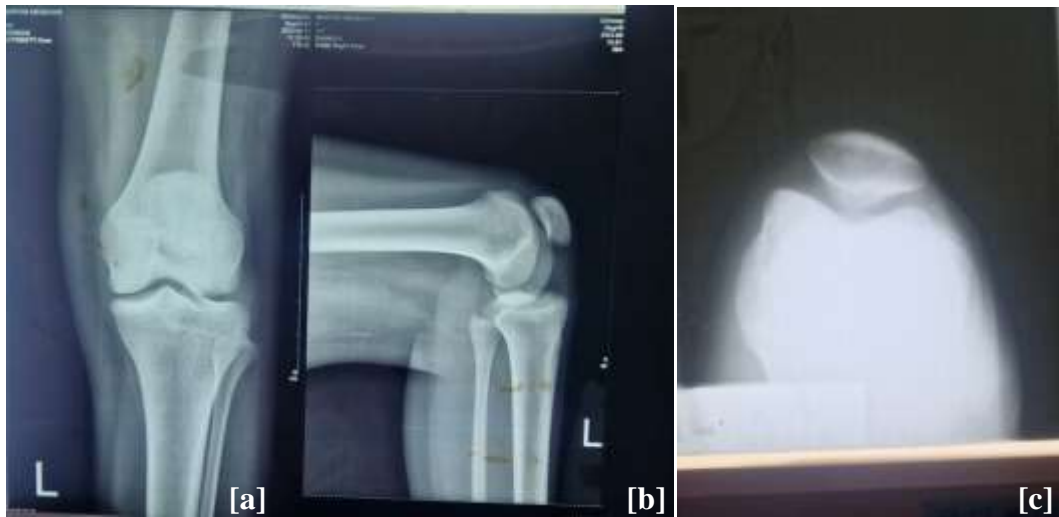

Figure 2: Preoperative radiograph of a 27 year female patient. Antero-posterior view(2a) and Sunrise view (2b)

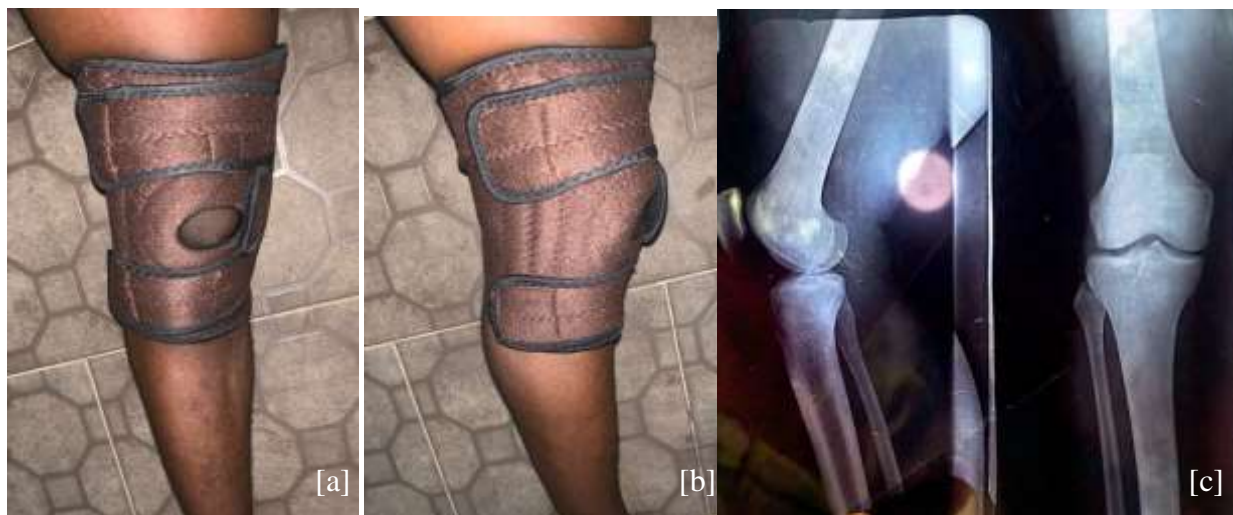

Figure 3: Conservative management of a 1 year post-traumatic right recurrent lateral patella dislocation in a 24 year old male patient. Use of knee brace (3a); Patient's radiograph was essentially normal (3b)

Conservative treatment

This comprises physiotherapy for quadriceps strengthening exercises, activity modification, use of analgesics in selected patients, and application of knee brace (Figure 3a). The usual duration for this type of treatment was for minimum 6 months duration after which patient was considered either responding to treatment or counselled for surgical intervention.

Operative procedure

Patients for operative procedures were selected based on the history of an increasing number of recurrent lateral patella dislocations, clinical and radiological findings, particularly with the presence of significant functional incapacitation and the lack of response to appropriate conservative treatment. The patient were counseled and optimized for surgery. A medial parapatella

approach was used with incision made through the skin and subcutaneous tissues (Figure 4a) and further advanced superiorly to expose both the MPFL and distal portion of VMO (Figure 4).

The MPFL was divided longitudinally and stay sutures were applied to hold the margins, which were later overlapped and multiple sutures applied to hold the flaps in place (Figure 4b). Following drilling of a hole through the medial side of the supracondylar area of the left femur, a 60mm cortical screw was passed and was used to anchor the overlapping edges of the MPFL and VMO in one place (Figure 4c). Multiple sutures were applied to secure the plication and also on the screw head to assist in holding the ligament in place and more medially oriented. No

releasing incision was made on the lateral parapatella area and no bony procedure was done. Stability was confirmed by manually shifting the patella laterally. The wound was subsequently closed in layers, and no drain was placed. Postoperatively, the patient was immediately commenced on gradual knee flexion between 0° and 80° of flexion, and full weight bearing as pain was tolerated with a knee brace for 45 days. Functional assessment was continued on follow-up (Figure 5) with a usual pattern of 6 weeks, 3 months, 6 months and 12 months. From the 6th month postoperatively, screws were removed on individual patient's basis after satisfactory return to full functions.

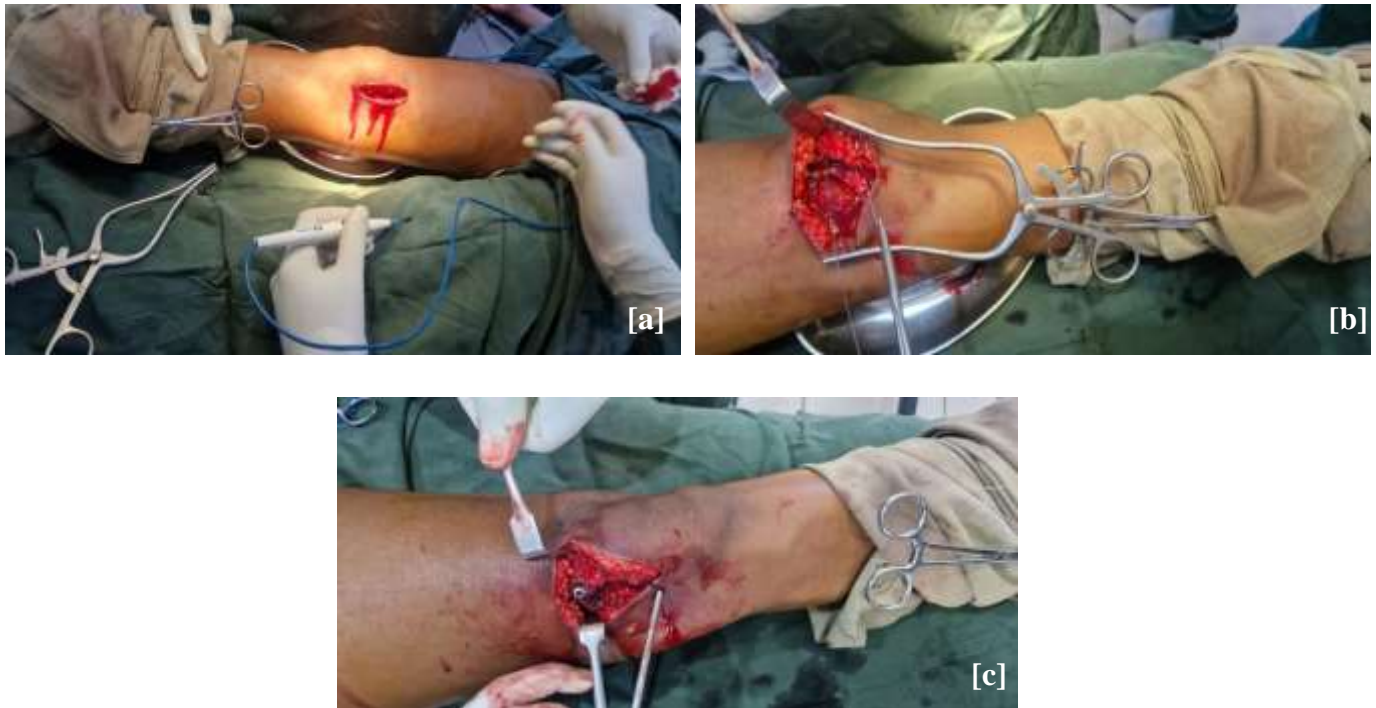


Figure 4: Intra--operative pictures. Medial parapatella incision (4a); Plication of MPFL (4b); Screw fixation anchor for the VMO tendon (4c)

Results

The average presentation time was 6.5 months (range 1 to 12 months), and the average age at presentation was 24 years (range 16 to 34 years). The average follow up period was 2.2 years (range 2 to 3.2 years). There were 7 males and 10 females; right knee affected were 7, and left knee were 8 with 2 bilateral knees affected (Table 1). Seven patients had history of knee trauma, while 10 patients had no history of trauma and among them, 8 had presence of generalised ligament laxity (Table 1 & 2). For the atraumatic patella dislocation group, the average Beighton score was 6 (range 2 to 9), the average Q angle was 150 (range 130 to 180), the trochlear morphology (Figure 2B) were all normal, and the average Caton-Deschamps index was 1.1 (range 0.8 to 1.3) (Table 2).

Among the 17 patients in the study, 12 were treated conservatively, and 5 were treated operatively. Out of the 5 treated operatively, 4 had plication of the MPFL with subsequent screw

fixation of the VMO tendon to the distal femur, and 1 patient with post-traumatic RPD had only plication of MPFL without screw fixation.

Immediate postoperative period, the 5 patients did not have any patella displacement, pain, or difficulty walking. The patients were very satisfied with the result of knee functional outcome with significant improvement of all the clinical scores. The average preoperative and postoperative Kujala scores were 68/100 and 94/100 points respectively, and that of Lysholm score were 72/100 and 96/100 points respectively.

At 1 year follow-up, 16 patients were fully treated and 1 patient, a 19 year old female who was treated conservatively recurred. While at 2 year follow-up, 12 patients were fully treated; a 17 year old male patient who was treated conservatively recurred; and 4 patients were lost to follow-up (LFU)(Table 1).

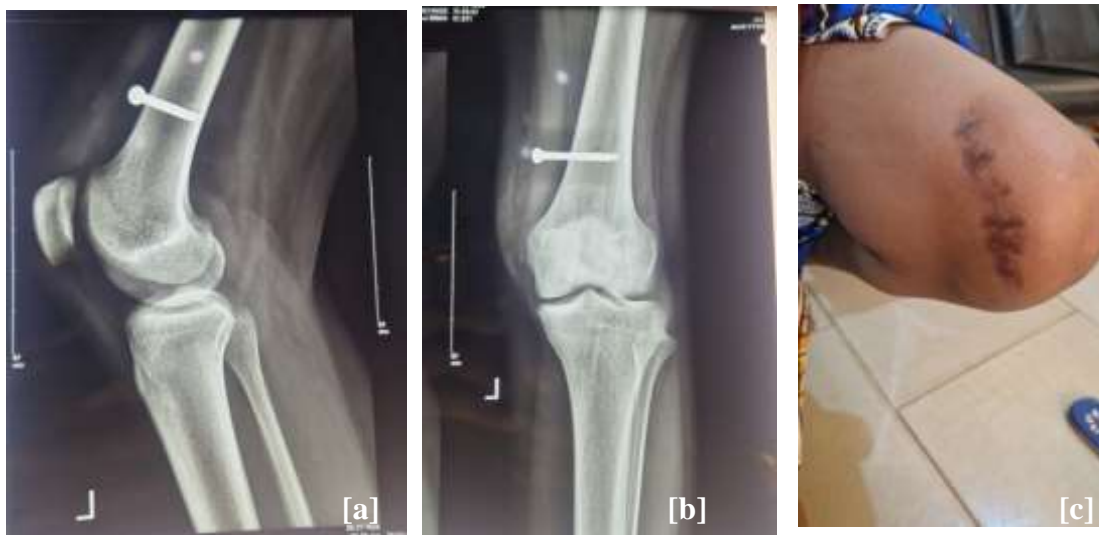


Figure 5: Postoperative radiograph (5a); Scar at 6 months follow-up (5b)

Table 2: Important findings in patients with atraumatic lateral patella dislocation (n=9)

Patient	Sex	Age	Side	Beighton score	Qangle	Trochlear Morphology	Caton-Deschamps Index	Treatment
1	F	18	Right	6	16 ⁰	Normal	1.1	Conservative
2	F	16	Bilateral	7	18 ⁰	Normal	1.23	Conservative
3	M	22	Right	5	15 ⁰	Normal	1.1	Operative
4	F	25	Left	3	16 ⁰	Normal	1	Conservative
5	F	20	Bilateral	9	17 ⁰	Normal	1.2	Conservative
6	F	27	Left	7	15 ⁰	Normal	1.3	Operative
7	F	24	Left	8	14 ⁰	Normal	0.9	Operative
8	M	17	Left	7	13 ⁰	Normal	1.2	Conservative
9	F	21	Left	7	15 ⁰	Normal	1.1	Operative
10	F	30	Right	2	14 ⁰	Normal	0.8	Conservative

Discussion

Recurrent patellar dislocation (RPD) has many aetiological factors including dysplastic patella, trochlea hypoplasia, a high Q angle, patella alta, tightness of lateral soft tissue structures, insufficiency of vastus medialis and valgus knee [21]. Another major aetiological factor for RPD is generalized joint laxity, which is one of the strong factors in the hereditary disposition for RPD [22]. In our study, 12 patients had ligament laxity related RPD, while 5 had trauma related RPD. Both groups benefited from both conservative and surgical intervention of medial parapatella soft tissue repair and screw fixations as reinforcement for more stability. Patients with RPD can be treated both conservatively and by surgical intervention. The result of non-operative treatment is unpredictable, and may end up requiring a more predictable surgical procedure [23]. However, there were cases of successful conservative treatment similar to our study reporting majority (n=12) to have been treated conservatively following at least 6 months treatment trials. No single option of operative procedure is best suited for the treatment of RPD and the surgical procedure varies according to the aetiology and pathology associated with RPD. These include the anatomical abnormality and severity of the RPD condition. The complexity of the surgical procedure is usually proportional to the complexity of the patho-anatomy of the patella dislocation disorder. The patello-femoral realignment procedures have an overall success rate of 20% to 70% [24]. These procedures

comprise proximal and distal realignment correction for patella instability. We employed the use of proximal realignment that alters the medial-lateral patella position either by construction or repair of the MPFL [25]. It has been reported that the lateral patellar dislocations has a clear association with medial soft tissue injuries and to sufficiently address these pathological changes associated in patellar instability, MPFL reconstruction is often the recommended surgical procedure [26]. A Systematic Review and Meta-analysis by Daniel K. et al reported a high percentage of return to sports in young patients after isolated MPFL reconstruction for chronic patellar instability; their short-term results demonstrated a low incidence of recurrent instability, postoperative apprehension positivity, and reoperations [27]. This MPFL reconstruction procedure has been popularised and performed on a large scale both as a single entity and in tandem with other procedures to correct soft tissue disorders or bony mal-alignment [28]. Besides from this, our patients benefited from additional screw fixation for further anchorage to ensure less chance of recurrence. The distal realignment which none of our patients had, repositions the patella more medially by transfer of the tibial tubercle [29].

Patients with generalised ligamentous laxity and RPD may have associated patho-anatomy of the patella particularly trochlear hypoplasia in which neither proximal nor distal realignment procedure alone may be adequate to address and correct the trochlear hypoplasia. This is corrected mainly by trochlear osteotomy which is difficult to perform with

unpredictable long-term outcome [30]. None of our patient has trochlear hypoplasia, or abnormal Q angle we therefore performed only proximal realignment procedure in form of MPFL and screw fixation as reinforcement of the medial structural repair. Because of ligamentous laxity state of our patients, no lateral retinacular release was offered as the releasing procedure has not been recommended in those patients who had MPFL repair or reconstruction [31]. The limitations of this study were small patients' sample size, even though larger sample size cannot be anticipated in such unusual disorders. A longer follow-up time may be needed to validate the true effectiveness of the management in the long run.

Conclusion

The outcome of conservative and surgical treatments for recurrent patella dislocation can be satisfactory if patients selection and appropriate treatment choice was offered. In cases requiring surgical procedure as a result of generalised ligamentous laxity, MPFL plication repair with VMO screw anchorage to the femur can be a key to a successful and a desirable long-term treatment outcome.

Conflict of interest

There is no conflict of interest

Funding

None

References

- [1] Seeley M, Bowman KF, Walsh C, Sabb BJ, Vanderhave KL. Magnetic resonance imaging of acute patellar dislocation in children: patterns of injury and risk factors for recurrence. *Journal of Pediatric Orthopaedics*. 2012 Mar 1;32(2):145-55.
- [2] Palmu S, Kallio PE, Donell ST, Helenius I, Nietosvaara Y. Acute patellar dislocation in children and adolescents: a randomized clinical trial. *J Bone Joint Surg Am*. 2008;90(3):463-470.
- [3] Shea KG, Nilsson K, Belzer J. Patellar dislocation in skeletally immature athletes. *Operative Techniques in Sports Medicine*. 2006 Jul 1;14(3):188-96.
- [4] Shah JN, Howard JS, Flanigan DC, Brophy RH, Carey JL, Lattermann C. A systematic review of complications and failures associated with medial patellofemoral ligament reconstruction for recurrent patellar dislocation. *The American journal of sports medicine*. 2012 Aug;40(8):1916-23.
- [5] Sanders TL, Pareek A, Johnson NR, Stuart MJ, Dahm DL, Krych AJ. Patellofemoral arthritis after lateral patellar dislocation: a matched population-based analysis. *The American journal of sports medicine*. 2017 Apr;45(5):1012-7.
- [6] Hevesi M, Heidenreich MJ, Camp CL, Hewett TE, Stuart MJ, Dahm DL, Krych AJ. The recurrent instability of the patella score: a statistically based model for prediction of long-term recurrence risk after first-time dislocation. *Arthroscopy: The Journal of Arthroscopic & Related Surgery*. 2019 Feb 1;35(2):537-43.
- [7] Burnei G, Răducan ID, Lală CG, Klinaku I, Marti TD, Burnei C. Patellar dislocation: etiopathogenic diagnosis and treatment methods. *Clin Surg*. 2020; 5. 2020;2852.
- [8] Huntington LS, Webster KE, Devitt BM, Scanlon JP, Feller JA. Factors associated with an increased risk of recurrence after a first-time patellar dislocation: a systematic review and meta-analysis. *The American journal of sports medicine*. 2020 Aug;48(10):2552-62.
- [9] Balcarek P, Milinkovic DD, Zimmerer A, Zimmermann F. Mental and physical health-related quality of life in patients with recurrent patellar dislocations—a generic and disease-specific quality of life questionnaire assessment. *Journal of Experimental Orthopaedics*. 2022 Jun 28;9(1):60.
- [10] Buchner M, Baudendistel B, Sabo D, Schmitt H. Acute traumatic primary patellar dislocation: long-term results comparing conservative and surgical treatment. *Clinical Journal of Sport Medicine*. 2005 Mar 1;15(2):62-6.
- [11] Nwachukwu BU, So C, Schairer WW, Green DW, Dodwell ER. Surgical versus conservative management of acute patellar dislocation in children and adolescents: a systematic review. *Knee Surgery, Sports Traumatology, Arthroscopy*. 2016 Mar;24:760-7.
- [12] Flores GW, de Oliveira DF, Ramos AP, Sanada LS, Migliorini F, Maffulli N, Okubo R. Conservative management following patellar dislocation: a level I systematic review. *Journal of Orthopaedic Surgery and Research*. 2023 May 30;18(1):393.
- [13] Migliorini F, Rath B, Tingart M, Meisen N, Eschweiler J. Surgical management for recurrent patellar dislocations in skeletally immature patients. *European Journal of Orthopaedic Surgery & Traumatology*. 2019 Dec;29:1815-22.
- [14] Du H, Tian XX, Guo FQ, Li XM, Ji TT, Li B, Li TS. Evaluation of different surgical methods in treating recurrent patella dislocation after three-dimensional reconstruction. *International Orthopaedics*. 2017 Dec;41:2517-24.
- [15] Aglietti P, Buzzi R, De Biase P, Giron F. Surgical treatment of recurrent dislocation of the patella. *Clinical Orthopaedics and Related Research (1976-2007)*. 1994 Nov 1;308:8-17.
- [16] Uimonen MM, Repo JP, Huttunen TT, Nurmi H, Mattila VM, Paloneva J. Surgery for patellar dislocation has evolved towards anatomical reconstructions with assessment and treatment of anatomical risk factors. *Knee Surgery, Sports Traumatology, Arthroscopy*. 2021 Jun;29:1944-51.
- [17] Cahill SV, Sharkey MS, Carter CW. Clinical assessment of generalized ligamentous laxity using a single test: is thumb-to-forearm apposition enough?. *Journal of Pediatric Orthopaedics B*. 2021 May 1;30(3):296-300.
- [18] Parikh SN, Lykissas MG, Gkiatas I. Predicting risk of recurrent patellar dislocation. *Current reviews in musculoskeletal medicine*. 2018 Jun;11:253-60.
- [19] Fithian DC, Powers CM, Khan N. Rehabilitation of the knee after medial patellofemoral ligament reconstruction. *Clinics in sports medicine*. 2010 Apr 1;29(2):283-90.
- [20] Lysholm J, Tegner Y. Knee injury rating scales. *Acta orthopaedica*. 2007 Jan 1;78(4):445-53.
- [21] Fithian DC, Nomura E, Arendt E. Anatomy of patellar dislocation. *Oper Tech Sports Med* 2001;9:102-11.
- [22] Runow A. The dislocating patella. Etiology and prognosis in relation to generalized joint laxity and anatomy of the

- patellar articulation. *Acta Orthop Scand Suppl* 1983;201:1-53.
- [23] R. Nikku, Y. Nietosvaara, P.E. Kallio, K. Aalto, J.E. Michelsson. Operative versus closed treatment of primary dislocation of the patella. *Acta Orthop Scand* 68 (1997) 419e423.
- [24] E. Nomura, M. Inoue. Cartilage lesions of the patella in recurrent patellar dislocation. *Am J Sports Med* 32 (2004) 498e502.
- [25] A. Tom, J.P. Fulkerson. Restoration of native medial patellofemoral ligament support after patella dislocation. *Sports Med Arthrosc* 15 (2007) 68e71.
- [26] Dewan V, Webb MS, Prakash D, Malik A, Gella S, Kipps C. When does the patella dislocate? A systematic review of biomechanical & kinematic studies. *Journal of Orthopaedics*. 2020 Jul 1;20:70-7.
- [27] Schneider DK, Grawe B, Magnussen RA, Ceasar A, Parikh SN, Wall EJ, Colosimo AJ, Kaeding CC, Myer GD. Outcomes after isolated medial patellofemoral ligament reconstruction for the treatment of recurrent lateral patellar dislocations: a systematic review and meta-analysis. *The American journal of sports medicine*. 2016 Nov;44(11):2993-3005.
- [28] Stupay KL, Swart E, Shubin Stein BE. Widespread implementation of medial patellofemoral ligament reconstruction for recurrent patellar instability maintains functional outcomes at midterm to long-term follow-up while decreasing complication rates: a systematic review. *Arthroscopy*. 2015;31(7):1372-1380.
- [29] Longo UG, Rizzello G, Ciuffreda M, Loppini M, Baldari A, Maffulli N, Denaro V. Elmslie-Trillat, Maquet, Fulkerson, Roux Goldthwait, and other distal realignment procedures for the management of patellar dislocation: systematic review and quantitative synthesis of the literature. *Arthroscopy: The Journal of Arthroscopic & Related Surgery*. 2016 May 1;32(5):929-43.
- [30] R. Kuroda, H. Kambic, A. Valdevit, J. Andrish. Distribution of patellofemoral joint pressures after femoral trochlear osteotomy. *Knee Surg Sports Traumatol Arthrosc* 10 (2002) 33e37.
- [31] Malatray M, Magnussen R, Lustig S, Servien E. Lateral retinacular release is not recommended in association to MPFL reconstruction in recurrent patellar dislocation. *Knee Surgery, Sports Traumatology, Arthroscopy*. 2019 Aug 1;27:2659-64.

Open Access This article is licensed under a Creative Commons Attribution 4.0 International License, which permits use, sharing, adaptation, distribution and reproduction in any medium or format, as long as you give appropriate credit to the original author(s) and the source, provide a link to the Creative Commons license, and indicate if changes were made. The images or other third party material in



this article are included in the article's Creative Commons license, unless indicated otherwise in a credit line to the material. If material is not included in the article's Creative Commons license and your intended use is not permitted by statutory regulation or exceeds the permitted use, you will need to obtain permission directly from the copyright holder. To view a copy of this license, visit <http://creativecommons.org/licenses/by/4.0/>.

© The Author(s) 2024