

Vertebro-Medullary Hydatid Cyst Case Report Diagnostic and Therapeutic Approach

Amel Djerbal ^{*1}, Kenza Badache ², Samir Tebani ¹, Yousria Akloul ¹, Souhila Sadat ¹, Dalila Zeghdoud ¹, Reda Harrar ¹

¹Faculty of Medicine, University of Algiers I, Specialized Hospital Establishment Salim Zemirli –El Harrach, Algiers.

²Faculty of Medicine, University of Algiers I, University Hospital Center of Algiers, Hospital of Algiers Mustapha, Algiers.

*Corresponding Author: Amel Djerbal; djeralamel@gmail.com

Received: 15 February 2024;

Revised: 05 March 2024;

Accepted: 10 March 2024;

Published: 25 March 2024

Abstract

Although rare, vertebral echinococcosis is a serious condition due to the neurological complications and therapeutic difficulties involved. The prognosis remains uncertain. Clinical symptoms are limited to pain with no specificity apart from signs of spinal cord or radicular compression. Diagnosis is difficult; conventional radiology may reveal certain indirect but highly suggestive signs, but the most accurate examination remains a CT scan and MRI. The possibility of certain serological tests can guide the diagnosis. Only surgical treatment can lead to a cure. Difficult total resection explains the frequency of recurrences and the multiplicity of operations, giving the disease a local malignancy. Medical treatment (Mebendazole) remains disappointing at present. Material and method: We report a case of thoracic vertebro-medullary hydatid cysts (HC) in a woman who underwent surgery. The diagnosis was based on clinical, biological and radiological examinations.

Introduction

Bone hydatidosis is a rare condition accounting for 0.5 to 2% of cases, despite being endemic in North African countries ^[1]. Bone involvement, described since 1801 by Cullerier, is rare. Vertebral echinococcosis poses difficult diagnostic, therapeutic and prognostic problems. It is a rare condition with certain "specificities" linked to the very nature of the disease and the parasite, which give it a particular dimension, combining a prolonged clinical latency, the difficulty of diagnosis and the frequency of medullary and radicular compressions, and the frequent impossibility of carrying out a complete surgical excision. From a radiological point of view, certain non-specific but frequently found signs are very useful for orientation ^[2], such as the unilateral nature of the lesions and the extent of lytic phenomena, although the bone architecture is very often preserved. The presence of these lesions is indicative of bacterial super infection, and the intervertebral discs have been preserved for a long time. In addition, a fundamental notion dominates the question: vertebral echinococcosis is often the only location of the parasite, and in all cases it never represents a form secondary to a visceral cyst. However, in 10% of cases there is a combination of these locations, resulting in the "multiple and parallel primary form" of GRISEL and DEVE ^[3].

The aim of this paper is to describe the various clinical, anatomical and radiological aspects of the disease. We also report our very brief experience of a case treated in the department.

Observation

The patient FB aged 51 years, living in Biskra with a history of allergy to penicillin and goiter under treatment, was admitted on 21 January 2020 to the department of orthopedics Salim Zemirli Hospital in Algiers, as an emergency for a dorsal spinal cord

compression. On admission, clinical examination revealed that the patient was conscious, presenting with a lesion syndrome of dorsalgia with intercostal neuralgia, and a sub-lesion syndrome of spastic para paresis. She presented with hypoesthesia of both lower limbs and urinary incontinence. The Babinski reflex was bilateral and the osteotendinous reflexes were fast. Telethorax revealed opacity at the left base of the lung, extending into the medullary axis. Magnetic resonance imaging (MRI) was performed, confirming the diagnosis of spinal echinococcosis by showing images of hydatid vesicles characterized by hyposignal on a T1 sequence and hypersignal on T2 sequences, posterior epidural intracanal spread in the thoracic region from T4 to T8 (Figure 1). There was no peripheral neuropathic involvement detected on EMG. The patient underwent bone marrow decompression by laminectomy of T4 to T8 followed by puncture of both cystic formations. For T5-T6 and T7-T8, the cystic parts were removed. The parasitological study was in favour of a hydatid cyst. The patient received medical treatment based on benzimidazole derivatives (albendazole). Histological examination revealed a hydatid membrane within regular trabeculae of bone (Figure 2). In 2021, the patient was readmitted as an emergency patient for spinal cord compression, presenting with the same clinical picture as the first hospitalization, Magnetic resonance imaging (MRI) was performed as an emergency, confirming the diagnosis of recurrence of 3 vertebro-medullary hydatid cysts extending from T3 to T8 with intracanal extension compressing the spinal cord, with myelopathy at T6 (Figure 3). The patient underwent dorsomedullary decompression followed by evacuation of the 3 hydatid cysts. The clinical course was subsequently favourable.

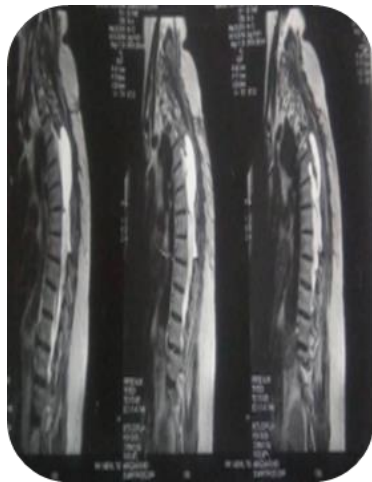

Figure 1: Coronal T1 gado section on the right, showing thoracic extension exerting a mass effect on the spinal column and its

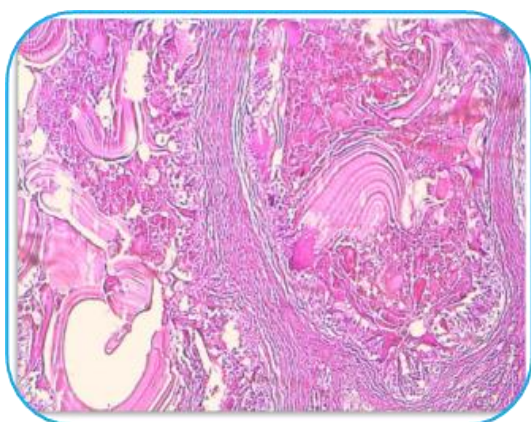


Figure 2: Hydatid membrane within regular bone trabeculae. (HES x 10)

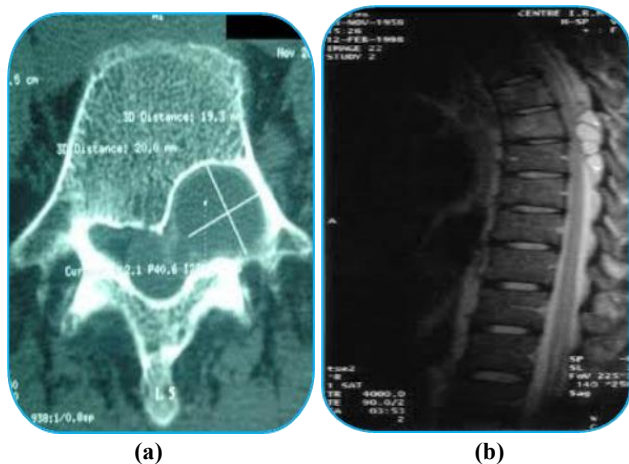


Figure 3: Multi-vesicular cystic formation.

(a): Intraosseous development Right dorsal foraminal extension.
 (b): Intra canal extra dural development with numerous cystic formations on the left.

Discussion

The hard consistency of the bone prevents the parasite from growing spherically and unilocularly. At this level, the development of the parasite takes place in 2 distinct phases. Firstly, true diverticula are formed by hydatids at the expense of the parasite membrane. Later, the diverticula isolate from the mother vesicle and transform into daughter vesicles. This type of development is known as exogenous vesiculation [4-7]. Structural changes take place, firstly in the cancellous bone, which is invaded first, and loses its characteristic

red colour [5]. Sequestrations form, while the trabecular structure of the vertebra has disappeared. All this intraosseous proliferation is insidious and painless, which explains the clinical latency frequently observed. On the other hand, the intra-spinal spaces where the larva develops are the same as in visceral forms, and the symptoms are more obvious because of the damage to the nervous system. Advanced spinal lesions give the appearance of a white hydatid vertebra (Figure 4).

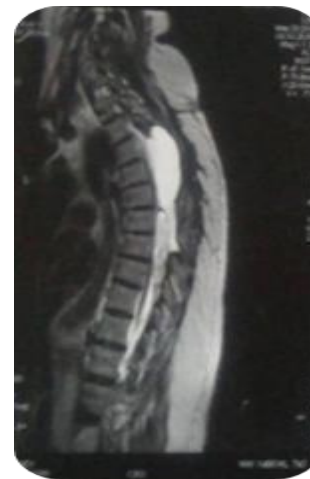

Figure 4: appearance of the white hydatid vertebra

Secondly, the lesion extends locally beyond the vertebra. It may reach the spinal canal and cause compression, muscular masses such as the psoas and give rise to ossifluent hydatid abscesses, the intervertebral disc at an advanced stage of the disease, neighboring vertebrae and the ribs, resulting in vertebro-costal forms which are very specific to echinococcosis, and finally the mediastinum. This extension takes on the character of a local malignancy due to the difficulty of total excision and recurrence, hence the term "white cancer".

Although widespread throughout the world, hydatidosis is endemic in Algeria. Its incidence is estimated at 0.9% (in 2017). It is an anthrozoosis caused by the development of the larval form of echinococcus granulosus. Humans are accidental hosts. Bone involvement is rare: 0.5 to 2.5% of hydatid sites [8]. It is due to the phenomenon of "paradoxical embolism", where a sudden increase in intra-abdominal pressure causes blood from the portal system to flow into the spinal plexus, bypassing the hepatic and pulmonary filters [9]. Vertebro-medullary hydatidosis affects the spinal column, accounting for 40-50% of bone sites, with decreasing interest in the dorsal (80%), lumbar (18%), sacral and cervical (1%) regions [10,11].

In our case, the posterior arch [12,13] of vertebro-medullary hydatidosis is located at the dorso-lumbar hinge. A fundamental notion is that the bone location is always primitive via the bloodstream. The clinical picture is very poor. Symptoms generally consist of non-specific vertebral pain, sometimes accompanied by deformity due to kyphosis or cystic swelling. Neurological signs are primarily motor deficits such as mono or paraparesis. They are the consequence of radicular or spinal cord compression and are the main cause of the gravity of this affection. On standard x-rays, the lesion initially appears as a lacunar osteolysis image, with poorly defined lacunae separated by dividing walls, creating a "grape cluster" appearance. At this stage, there is no perimeter condensation, and the cortical bone, bone morphology and intervertebral discs are preserved [2]. It is only at a later stage that the lesion progresses to the neighboring bones, with costovertebral involvement being fairly suggestive. The existence of a reconstruction process indicates super infection, which removes any specificity from the radiological images. In addition, a number of indirect signs suggest intrarachid involvement [2], such as an increase in interpedicular distance, pedicular deformity or lysis, and involvement of the posterior arch. Ultrasound is an innocuous and

easily repeatable examination, and the appearance is that of a fluid collection with central hyperechoic areas, reflecting multi-vesicular hydatid collections bathed in a dense puriform fluid [2]. Computed tomography (CT) is remarkably accurate and, in the event of bone involvement, can be used to visualise more or less delineated hypodense images of the centre of the bone. It can also be used to assess the appearance of the cortical bone, bone deformities where they exist and any costal involvement. Finally, para-vertebral collections can also be identified hydatid vesicles, in their typical form, appear oblong on MRI, in the shape of a "flattened sausage", with very thin walls and a purely liquid signal (hyposignal in T1, hypersignal in T2). Occasionally, the appearance is less typical and the difference in intensity on T2-weighted sequences which, according to some authors, makes it possible to determine the viability of cysts [14-16]. MRI is therefore an excellent examination for the pre-therapeutic evaluation of vertebro-medullary hydatidosis, and is sufficient firstly to confirm the hydatid nature of the abscess, secondly to determine the extent of the lesions and thirdly to determine the degree of viability of the vesicles and therefore the prognosis and long-term monitoring of possible recurrences [17]. Pott's disease is the main differential diagnosis, and the radiological images produced are reminiscent of vertebral echinococcosis. F. DEVE speaks of hydatid Pott's disease. Other conditions may be discussed, such as aneurysmal cysts of the bone, fibrous dysplasia, syphilis and osteomyelitis, and to a lesser extent chondroma, sarcoma, osteoblastoma and hyperparathyroidism. Serological tests are particularly useful in this context [4-7]. Surgery is the only way to achieve a definitive cure for the disease. The aim is to remove the parasite and, if possible, the residual cavity. Echinococcosis is always treated surgically, by radiculo-medullary decompression. The most commonly adopted approach is decompressive laminectomy and excision of the hydatid cysts, but this is often difficult, sometimes mutilating, and does not protect against recurrence. Recurrence is very frequent because cyst resection is often incomplete and bone infiltration is poorly limited. Chemical sterilisation of the scolex intraoperatively (hydrogen peroxide and formalin) remains of uncertain efficacy [18]. The role of medical treatment based on benzimidazole derivatives (albendazole) is not negligible for some authors. It has been shown to improve symptomatology in some cases [19,20], but its efficacy on the evolution and sterilization of lesions is still the subject of debate [18,17]. It has a place in inoperable forms, or in cases where surgery is refused, but also as adjuvant treatment. The prognosis for vertebral-medullary HC is therefore guarded, as recurrences are frequent and the neurological risk accentuates the importance of prevention [17,21,8].

Conclusion

Vertebro-medullary hydatidosis poses diagnostic and, above all, therapeutic difficulties, due to the large number of recurrences, even though surgery is often extensive and mutilating. The neurological and functional prognosis depends on the severity of the preoperative lesions. Follow-up with CT and MRI scans enables early diagnosis of recurrences, even before the onset of clinical signs. Albendazole appears to be the drug of choice, although the duration of treatment is controversial. Bone hydatidosis has a high morbidity and mortality rate. It is often discovered at the stage of neurological complications and difficulties with surgical eradication. The overall prognosis for bone echinococcosis remains poor, particularly for spinal echinococcosis. Although bone hydatidosis is a parasitic disease, its prognosis should be treated as if it were a malignant lesion. The spinal location of a hydatid cyst is rare, but serious, because of its consequences for neurological function. The disease progresses insidiously, with frequent recurrences, making the prognosis poor. The best treatment is prevention.

Funding

The authors did not receive any specific funding for this work

Conflict of interest

None

Ethics approval

Not Applicable

Data availability

Available upon request

References

- [1] AKAHADDAR A, GOURINDA H, EL ALAMI Z, EL MADHI T, MIRI A-Kyste hydatique du sacrum chez une adolescente. A propos d'un cas. *Rev Rhum Ed Fr.* 1999, 66(5) : 331-333.
- [2] TAZI Z, BOUDJIDA N, BOUKHRIS N : Hydatidose vertébro-médullaire. Apport de la radiologie et de la tomodensitométrie. A propos de 36 observations. *J. Radiol.*, 1965, 66. 183-188.
- [3] PSOMOPOULOS N, VLACHAKIS Th, BALAROUT-SOS Ch : L'échinococcose osseuse. A propos d'un cas de kyste hydatique de la colonne vertébrale. *J. Chir. (PARIS)*, 1976. III, N° 2, 207-210.
- [4] ARGENSON C, GRIFFET J, LACOUR C, ARCAMONE H, LOVET J : L'hydatidose vertébrale. A propos de 2 cas. *Rev. Chir. Orthop.*, 1989, 75. 267-270.
- [5] BETTAIB A., KHALDI M, BENROUMA T, TOUIBIS S. : L'échinococcose vertébro-médullaire. A propos de 32 cas. *Neurochirurgie.* 1978. 24, 205-210.
- [6] CARDONA J.M, GINE J, FIOFIES X, ALGÁRA C, BALLESTER J : Deux cas d'hydatidose vertébrale traités par association. *Chirurgie et mebendazole.* *Rev.chir.orthop.* 1983, 59. 69-74.
- [7] DURAH H. FERRANDEZ L., GONEZ-GASTRESANA F et A.J : Osseae hydatidosis. *J.B.J.S.*, 1978, 60. 985-990.
- [8] ZLITNI M, KOOLI M, EZZAOUIA K, LEBIB H, MESTIRI M –*Manifestations Osseuses des parasitoses. EMC Appareil locomoteur; 1996,14-021-B-10.*
- [9] BRUSCHI F, ORTONA E, IOPPOLO S, SIRACUSANO A & BONADIO M - *Immuno chemical and molecular characterization of vertebral hydatid fluid. ScandJ Infect Dis, 1999, 31,322-323.*
- [10] GARCIA-VICUNAR, CARVAJALI, ORTIZ-GARCIAA, LOPEZ ROBLEDILLO JC,LAFFO A&SABANDOP-*Primary solitary echinococcosis in cervical spine.Spine,2000,25, 520-523.*
- [11] HAMDENT A& AL-KAISYA-Dumbbell hydatid cyst of the spine. *Spine, 2000,25, 1296-1299.*
- [12] KELLER TM, SCHWEITZER JS, HELFEND LK & CHAPPEL T –*Treatment of progressive cervical spine instability secondary to hydatid disease. A case report. Spine, 1997, 22,915-917.*
- [13] PANDEYM &CHAUDHARIP-*Primary hydatid cyst of sacral spinal canal: case report. Neurosurgery, 1997, 40,407-409*
- [14] BRIANT JF, RICHE ZP, BELLIOLE E, BAREA D, RAILLAT A et al-*Atteinte ostéo articulaire d'origine parasitaire : L'échinococcose osseuse. JRadiol, 1998, 79,1351- 1357.*

- [15] *KABBAJ-EL KOUHEN N, DAFIRIR, EL OUAHABIA, EL KHAMLICHI A & IMANI F Kyste hydatique intra dural lombaire isolé. J. Radiol, 1999, 80,147-149.*
- [16] *TSITOURIDIS I & DIMITRIADIS A S-CT and MRI invertebral hydatid disease. Eur Radiol, 7, 1207-1210.*
- [17] *EVLIYAOGU C, KESKIL S. Possibles pontaneous "birth" of a hydatid cyst in to the lateral ventricle. Chlids Nerv Syst, 2005; 21:425-*
- [18] *ELANDALOUSSI M, YOUSRI B & ABOUMAAROUF M-Hydatidose vertébrale. A propos de trois cas. Rev Chir Orthop, 2001,87,392-396.62001,87,392- 396.8.*
- [19] *BHATOEH S, BAKSHIS S & SWAMYG LN-Trichino echinococcosis T5. J Neuro surg, 2000, 92,225-228.*
- [20] *LARBAOUI D, ALLOULA R, (1979). « Etude épidémiologique de l'hydatidose en Algérie : résultats de 2 enquêtes rétrospectives sur 10 ans.*
- [21] *HERNIGOU P, NABIHA & GOUTALLIER D-Hydatidose vertébrale : complication, apport de l'imagerie moderne. Rev. Page 4.*



Open Access This article is licensed under a Creative Commons Attribution 4.0 International License, which permits use, sharing, adaptation, distribution and reproduction in any medium or format, as long as you give appropriate credit to the original author(s) and the source, provide a link to the Creative Commons license, and indicate if changes were made. The images or other third party material in this article are included in the article's Creative Commons license, unless indicated otherwise in a credit line to the material. If material is not included in the article's Creative Commons license and your intended use is not permitted by statutory regulation or exceeds the permitted use, you will need to obtain permission directly from the copyright holder. To view a copy of this license, visit <http://creativecommons.org/licenses/by/4.0/>.

© The Author(s) 2024