

Incarcerated Intestine by Testicular Mass in Huge Scrotum: A Case Report

Ahmad Reza Shahraki *

General Surgeon, Department of Surgery, Medical Faculty, Zahedan University of Medical Sciences and Health Services, Zahedan, Iran.

*Corresponding author: Ahmad Reza Shahraki; a.r_sh@yahoo.com

Received: 16 January 2024; **Revised:** 15 February 2024; **Accepted:** 19 February 2024; **Published:** 23 February 2024

Abstract

Large testicular tumor is not a commonly seen entity in the modern era. While treatment of large testicular tumors is via inguinal radical orchiectomy, large testicular tumors carry the dilemma of delivering these large masses via the inguinal or scrotal approach.

Our case was a 90 years old man with obstruction signs and huge scrotum that shows incarcerated large bowel with huge testicular mass, that in his surgery we did Radical Orchiectomy and we replace incarcerated Large Bowel in scrotum and discharge him successfully. Giant testicular cancer is considered one of the largest testicular masses in the world. Delayed seeking medical advice and appropriate management is the major cause behind this rare presentation. Increasing the awareness regarding self-examination and eliminating the stigma is the cornerstone to markedly reduce this type of unusual presentation since any testicular size change and mass can be easily noted by the patient.

Surgical exploration and adjuvant chemotherapy seems as a reasonable treatment option in the setting of bilateral intra-abdominal testis tumor in an adult patient. The study underscores the effectiveness of the intervention in promoting preventive behaviours against testicular cancer among university students, laying the groundwork for future educational initiatives. Although testicular cancer (TC) is the most common malignancy in males between the ages of 18 and 50 years, little effort has been made to increase public awareness about TC and testicular self-examinations (TSEs). Intestinal obstruction without a past surgical history of abdominal surgeries or trauma is a rare and challenging clinical situation. This case report describes the presentation, diagnosis, and management of intestinal obstruction in a patient with an uncommon aetiology of small bowel obstruction. Chronic hernia incarceration can lead to weakening and ischemia of the bowel, and minimal trauma can lead to perforation of the weakened segment. In such presentations, bowel resection and repair of the defect with a biological material is safe and feasible.

Keywords: *Sarcoma, Large bowel, mass, testis, tumor, testicular cancer, Incarcerated bowel, Intestinal obstruction, Case report.*

Introduction

Large testicular tumor is not a commonly seen entity in the modern era. While treatment of large testicular tumors is via inguinal radical orchiectomy, large testicular tumors carry the dilemma of delivering these large masses via the inguinal or scrotal approach [1]. Testicular cancer is considered a rare malignancy globally; in this regard, testicular cancer is appraised as a disease of young and adult men. Although it can manifest in childhood with a reported percentage of 7%, the mean age of incidence in general population is between the ages of 20 and 34 years [2]. Considerable risk factors such as age, ethnicity, family history of testicular cancer, and cryptorchidism are acknowledged as well [3]. Testicular germ cell tumors (TGCTs) are the most frequently encountered type of testicular cancer. Histologically, TGCTs are categorized into three categories: seminomas, nonseminomas, and spermatocytic seminomas with the seminomas and nonseminomas count as the majority of TGCT as much as 98%–99% [4]. Testicular cancer may present in different ways such as painless scrotal swelling, incidental finding in radiological imaging, and posttraumatic or metastatic symptoms. As that as it may be, the U.S. Preventive Task Force opposes screening for testicular cancer in asymptomatic young and adult patients with

no testicular cancer risk. However, the American Cancer Society does recommend testicular examination as part of the routine cancer-related checkup [4]. Presence of any kind of solid mass in the testis should it be identified by physical examination, or imaging is ought to be managed as a malignancy until proven otherwise [5]. The AUA guideline promotes the investigation of any suspicious solid mass in the testis with initial imaging by Doppler ultrasound and serum tumor markers, which consist of alpha-fetoprotein (AFP), human chorionic gonadotropin (hCG), and lactate dehydrogenase (LDH). Findings of hypoechoic mass with vascular flow on the US investigation is highly skeptical of testicular conserve [5]. The standardized initial management of unilateral testicular cancer at the existence of normal contralateral testis is radical inguinal orchiectomy [4]. An attempt of taking trans-scrotal testicular biopsy should not be carried out as it may disturb the lymphatic drainage of the tumor and spoil the scrotum. The sample of the radical inguinal orchiectomy must be sent for histopathological interpretation [6]. Testicular cancer treatment and prognosis plan is made in multi-multidisciplinary structure formula that involves histopathology, clinical staging, prognosis of the disease, and specialist–patient debate on positive and negative outcomes of the treatment. However, adjusted modified treatment plans based on risk-adapted

therapy in nonseminoma patients are yet to prove its worth seminoma patients [3]. Intestinal obstruction without a past surgical history of abdominal surgeries or trauma is a rare and challenging clinical situation. This case report describes the presentation, diagnosis, and management of intestinal obstruction in a patient with an uncommon aetiology of small bowel obstruction [17]. Some cases can be successfully treated with emergent laparoscopic surgery [18].

Case presentation

Our case was a 90 years old man that referred to surgery part with abdominal pain, we admit him and start examination, we find huge scrotum that was carried for 2 days (Figure 1)

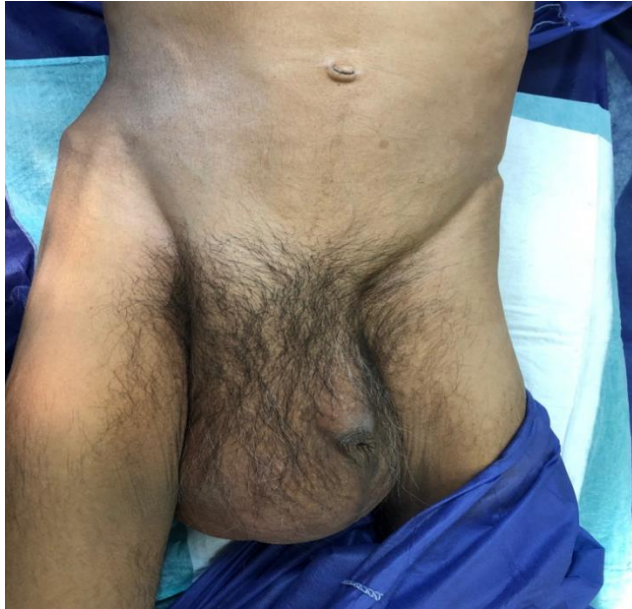

Figure1: Huge scrotum

We continue our assessment and we find sign and symptoms of intestinal obstruction and did Ultrasonography that shows bowel in scrotum and we prepare him for surgery with incarcerated intestine with inguinal approach (Figure 2).

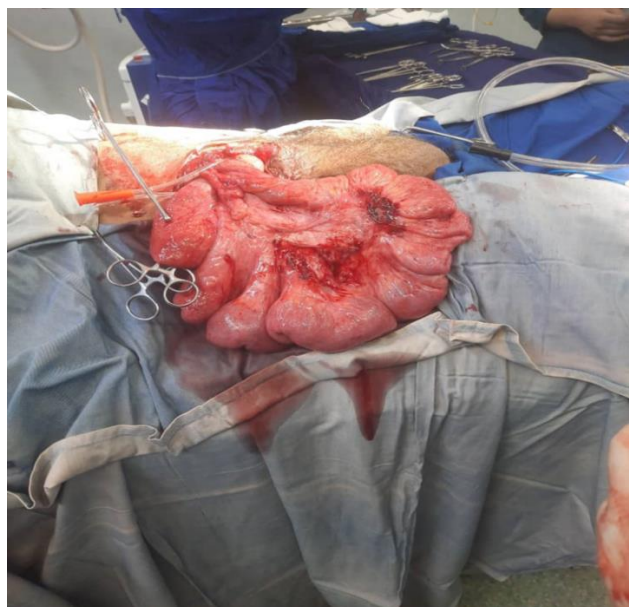


Figure 2: Incarcerated intestine

With continuous surgery to check testis we find a testicular mass that pulled intestine into the scrotum (figure3)

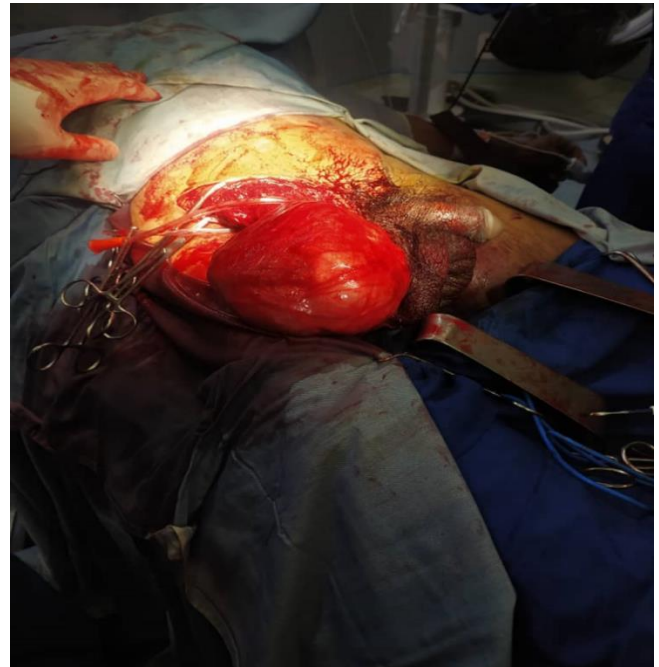

Figure 3: Testicular mass

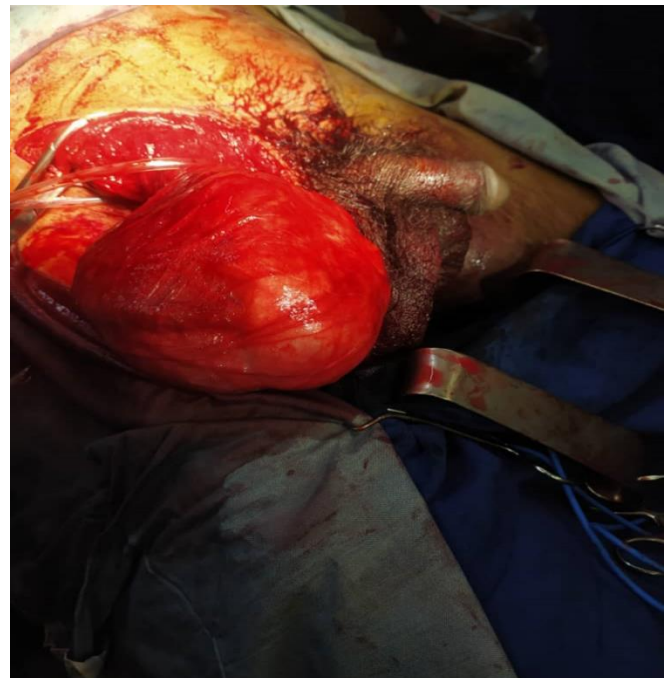

Figure 3: Testicular Mass

We did Radical orchiectomy by inguinal approach and replace intestine in abdomen and repair inguinal hole by tissue flap. After 2 days patient has defecation and we discharge him healthy and successfully.

Discussion

The advances seen in the treatment of testicular cancer are among the great achievements in modern medicine. These advances were made possible by the collaborative efforts of cancer researchers around the world. Investigators have been able to address many questions regarding the treatment of patients with disease limited to the testis, those with metastasis to the retroperitoneum only, and

those with advanced metastatic disease. Questions answered include the chemotherapeutic agents to be used and in what combinations, the proper intensity of treatment and appropriate dosing, the optimal number of cycles of chemotherapy according to validated risk stratification, appropriate surgical approaches that preserve sexual function, the treatment of relapsed disease, what supportive care measures to take, and survivorship issues following treatment of testicular cancer. Today, cure is achievable in 95% of all patients with testicular cancer and 80% of those who have metastatic disease. Despite remarkable results with frontline and salvage combination chemotherapy, metastatic testicular cancer remains incurable in approximately 10% of patients, and novel treatment approaches are warranted. This review highlights past and recent discoveries in the treatment of patients with testicular cancer^[6]. Testicular cancer is the most common type of malignancy in young adult males, accounting for 1% of all cancer diagnosis in men and 5% of all urologic tumors. It is one of the malignancies with the highest cure rate. Bilateral germ cell tumor of the testicles is rare, representing only 1% of all new cases of testicular cancer, around 30% of which occur synchronously. Interestingly, there is not yet an occurrence where the bilateral synchronous testicular cancer has different histopathological type^[7]. Known risk factors for testicular cancers include cryptorchidism, prior testicular germ cell tumor (TGCT), having a father with TGCT, having a brother with TGCT, and higher body height. Prior testicular germ cell tumor (TGCT) and higher body height are the risk factors that are found in this patient's case. Among these factors, the greatest relative risk is having a brother with testicular TGCT, increasing the individual's risk by approximately 10 times (RR 7.55–12.74, 95% CI), followed by history of cryptorchidism (RR 4.3, 95% CI)^[8]. A review of the related literature in recent years reveals several reports of TMGCTs manifesting with fever and lymph node enlargement, which may be explained by the undetectable onset of the disease as well as limited knowledge of the disease to date. The diagnostic process and treatment plan for this patient may serve as a reference in clinical practice^[10]. Giant testicular cancer is considered one of the largest testicular masses in the world. Delayed seeking medical advice and appropriate management is the major cause behind this rare presentation. Increasing the awareness regarding self-examination and eliminating the stigma is the cornerstone to markedly reduce this type of unusual presentation since any testicular size change and mass can be easily noted by the patient^[11].

Conclusion

Giant testicular cancer is considered one of the largest testicular masses in the world. Delayed seeking medical advice and appropriate management is the major cause behind this rare presentation. Increasing the awareness regarding self-examination and eliminating the stigma is the cornerstone to markedly reduce this type of unusual presentation since any testicular size change and mass can be easily noted by the patient. Treatment with surgery and chemotherapy is well tolerated and received. A further specific clinical study needs to be performed to investigate this finding in the future^[7]. Surgical exploration and adjuvant chemotherapy seems as a reasonable treatment option in the setting of bilateral intra-abdominal testis tumor in an adult patient^[9]. Giant testicular cancer is considered one of the largest testicular masses in the world. Delayed seeking medical advice and appropriate management is the major cause behind this rare presentation. Increasing the awareness regarding self-examination and eliminating the stigma is the cornerstone to markedly reduce this type of unusual presentation since any testicular size change and mass can be easily noted by the

patient^[11]. In conclusion, the present case report underscores the rarity and slow-growing nature of testicular ScTs, emphasizing the significance of prompt identification and treatment. Clinical examination, tumor markers, and imaging techniques are vital for accurate diagnosis. Radical orchidectomy is crucial for ensuring favorable outcomes, and long-term monitoring is necessary to detect any potential recurrence or spread^[12]. The study underscores the effectiveness of the intervention in promoting preventive behaviours against testicular cancer among university students, laying the groundwork for future educational initiatives^[13]. Our data on testicular GCT including demographic, histological, and treatment outcomes were comparable to that of developed countries. In light of the pathology discrepancy rate revealed in our study, authors recommend a second review by expert genitourinary pathologists to ensure proper classification and management of GCT^[14]. Mixed germ cell tumours with choriocarcinoma components are rare and tend to affect younger populations. These tumours demonstrate aggressive clinical behaviour, with a significant proportion presenting with high-grade lesions and metastasis at diagnosis. The observed mortality rate underscores the poor prognosis associated with this malignancy^[15]. Although testicular cancer (TC) is the most common malignancy in males between the ages of 18 and 50 years, little effort has been made to increase public awareness about TC and testicular self-examinations (TSEs)^[16]. The importance of considering rare etiologies in patients with abdominal pain, especially those lacking a typical history, is emphasized. The effective use of imaging and tailored surgical approach was key to the successful outcome. This report adds to the limited literature on omental breaches causing intestinal obstruction and underlines the necessity of a multidisciplinary approach in such cases^[17]. Some cases can be successfully treated with emergent laparoscopic surgery^[18]. Chronic hernia incarceration can lead to weakening and ischemia of the bowel, and minimal trauma can lead to perforation of the weakened segment. In such presentations, bowel resection and repair of the defect with a biological material is safe and feasible^[19]. Generally some problem can effect on this situation: The discussed case is extremely rare. The case's novelty is that it is a true hernia in an orthopedic surgery wound of the iliac wing ORIF, the clinical presentation and the surgical treatment used. There are not enough data about the epidemiology, prognosis or treatment guidelines. Reviewing the previous literature, we did not find any article describing a similar condition^[20]. In herniorrhaphy with mesh, minimization of bowel resection is important for preventing postoperative infection of the mesh. In this case, ICG fluorescence with a near-infrared fluorescence camera was central to reducing bowel resection^[21].

Declarations

Ethical Approval and Consent to participate:

The content of this manuscript are in accordance with the declaration of Helsinki for Ethics. No committee approval was required. Oral and written consent to participate was granted by the parents.

Consent for publication

“Written informed consent was obtained from the patient's legal guardian for publication of this case report and any accompanying images. A copy of the written consent is available for review by the Editor-in-Chief of this journal.”

Availability of supporting data

It is available.

Competing interests:

The author declares that they have no competing financial interests and nothing to disclose.

Funding

There is no funding.

Authors' contributions

Ahmad Reza Shahraki was the surgeon of patient and writes this paper.

The author declares that they have no competing financial interests and nothing to disclose.

Acknowledgements

In abdomen you can face with verified problem and should notice to scrotum in examination of patient with abdominal pain.

References

- [1] Alaskari MM, Hassan IAB, Aldakhil TA, Al Khatem RS. A case report of large testicular mass: An Eastern Province report from KSA. *Urol Ann.* 2023 Jan-Mar; 15(1):101-103. doi: 10.4103/ua.ua_14_22. Epub 2023 Jan 17. PMID: 37006219; PMCID: PMC10062520.
- [2] Abomelha M. Adult testicular cancer: Two decades of Saudi national data. *Urol Ann.* 2017 Oct-Dec; 9(4):305-309. doi: 10.4103/UA.UA_11_17. PMID: 29118528; PMCID: PMC5656951.
- [3] Baird DC, Meyers GJ, Hu JS. Testicular Cancer: Diagnosis and Treatment. *Am Fam Physician.* 2018 Feb 15;97(4):261-268. PMID: 29671528.
- [4] Ghazarian AA, Trabert B, Devesa SS, McGlynn KA. Recent trends in the incidence of testicular germ cell tumors in the United States. *Andrology.* 2015 Jan;3(1):13-8. doi: 10.1111/andr.288. Epub 2014 Oct 20. PMID: 25331158; PMCID: PMC4342271.
- [5] tephenson A, Eggener SE, Bass EB, Chelnick DM, Daneshmand S, Feldman D, Gilligan T, Karam JA, Leibovich B, Liauw SL, Masterson TA, Meeks JJ, Pierorazio PM, Sharma R, Sheinfeld J. Diagnosis and Treatment of Early Stage Testicular Cancer: AUA Guideline. *J Urol.* 2019 Aug;202(2):272-281. doi: 10.1097/JU.0000000000000318. Epub 2019 Jul 8. PMID: 31059667.
- [6] Adra N, Einhorn LH. Testicular cancer update. *Clin Adv Hematol Oncol.* 2017 May;15(5):386-396. PMID: 28591093.
- [7] Ginting JT, Sihombing B, Warli SM, Siregar GP, Prapiska FF. Bilateral synchronous testicular cancer: A case report. *Int J Surg Case Rep.* 2023 Feb;103:107870. doi: 10.1016/j.ijscr.2022.107870. Epub 2023 Jan 4. PMID: 36640464; PMCID: PMC9840355.
- [8] Campobasso D, Ferretti S, Frattini A. Synchronous bilateral testis cancer: clinical and oncological management. *Contemp Oncol (Pozn).* 2017;21(1):70-76. doi: 10.5114/wo.2017.66660. Epub 2017 Mar 22. PMID: 28435402; PMCID: PMC5385482.
- [9] Fatih Sandikci, Sertac Cimen, Sanem Guler Cimen, Goksen Inanc Imamoglu, Unsal Han, Alihan Kokurcan, Burhan Baylan, Goksel Goktug, Abdurrahim Imamoglu, Bilateral intra-abdominal testicular tumor: Case report, *International Journal of Surgery Case Reports*, Volume 49, 2018, Pages 102-105, ISSN 2210-2612, <https://doi.org/10.1016/j.ijscr.2018.06.027>.
- [10] Xiao QF, Li J, Tang B, Zhu YQ. Testicular mixed germ cell tumor: A case report. *World J Clin Cases* 2023; 11(28): 6902-6907 [PMID: 37901019 DOI: 10.12998/wjcc.v11.i28.6902].
- [11] Alaskari, Mohammed Mansour; Hassan, Islam A. Bary; Aldakhil, Talib Abdulaziz; Al Khatem, Raihanah Saeed¹. A case report of large testicular mass: An Eastern Province report from KSA. *Urology Annals* 15(1):p 101-103, Jan-Mar 2023. | DOI: 10.4103/ua.ua_14_22.
- [12] Bapir R, Aghaways I, Ali RM, Fakhralddin SS, Ali RM, Rashid RJ, Abdullah AM, Ali MA, Mohammed KK, Abdullah HO, Abdullah HO, et al: Spermatocytic tumor of the testis: A case report and mini-review of the literature. *Med Int* 3: 51, 2023.
- [13] Ibrahim AM, Fathi Zaghamir DE. Enhancing Testicular Cancer Prevention Among University Students: A Health Belief Model and Social Support Intervention. *Asian Pac J Cancer Prev.* 2024 Feb 1;25(2):609-616. doi: 10.31557/APJCP.2024.25.2.609. PMID: 38415548; PMCID: PMC11077125.
- [14] El-Achkar A, Alasadi H, El-Asmar J, Armache A, Abu-Hijleh R, Abu-Hijle F, Al-Ibraheem A, Khzouz J, Salah S, Shahait M. Clinical characteristics and treatment outcomes of germ cell tumor in Jordan: A tertiary center experience. *Arab J Urol.* 2023 Jan 3;21(4):233-239. doi: 10.1080/2090598X.2022.2163473. PMID: 38178954; PMCID: PMC10763583.
- [15] Al-Khayal A, Noureldin Y, Alghafees M, Shafqat A, Sabbah BN, Elhossiny AH, Bakir M, Omar MA, Arabi TZ, Abdul Rab S, Alsaikhan B, Aldhalaan R, Alquirnas M, Alrabeeah K. A decade in focus: mixed germ cell tumors with choriocarcinoma components. *Ann Med Surg (Lond).* 2023 Sep 20;85(11):5355-5358. doi: 10.1097/MS9.0000000000001314. PMID: 37915675; PMCID: PMC10617832.
- [16] Alkhayal A, Alsaikhan BH, Alhajress G, Alsaghyir A, Noureldin YA, Aldraihem K, Alrabeeah K. Perceptions of testicular cancer and self-examination in the general population of Saudi Arabia. *Urol Ann.* 2023 Jul-Sep;15(3):266-270. doi: 10.4103/ua.ua_62_22. Epub 2023 Jun 16. PMID: 37664094; PMCID: PMC10471814.
- [17] Chaouch MA, Taieb AH, Jallali M, Chedly E, Gafsi B, Noomen F. Rare case report of intestinal obstruction due to incarcerated small bowel in omental breach. *Int J Surg Case Rep.* 2024 Feb;115:109245. doi: 10.1016/j.ijscr.2024.109245. Epub 2024 Jan 11. PMID: 38217921; PMCID: PMC10826806.
- [18] Chaouch MA, Taieb AH, Jallali M, Chedly E, Gafsi B, Noomen F. Rare case report of intestinal obstruction due to incarcerated small bowel in omental breach. *Int J Surg Case Rep.* 2024 Feb;115:109245. doi:

10.1016/j.ijscr.2024.109245. Epub 2024 Jan 11. PMID: 38217921; PMCID: PMC10826806.

236,ISSN

2210-

2612,https://doi.org/10.1016/j.ijscr.2016.11.041.

- [19] Hakiman, H., DeLibero, J., Pham, T. et al. Coughing-induced bowel transection in a patient with an incarcerated inguinal hernia: a case report. *J Med Case Reports* 7, 47 (2013). <https://doi.org/10.1186/1752-1947-7-47>.
- [20] Mohammad Abu-Jeyyab, Mohammad Al-Jafari, Ibraheem M AlKhalwaldeh, Sadeen Zein Eddin, Sophia Abu Tapanjeh, Mohannad Ja'Awain, Emad Aborajooh, Abdulqadir J Nashwan, Incarcerated incisional hernia on an old orthopedics incision, a rare case report and a review of the literature, *Journal of Surgical Case Reports*, Volume 2024, Issue 5, May 2024, rjae369, <https://doi.org/10.1093/jscr/rjae369>.
- [21] Shunjin Ryu, Masashi Yoshida, Hironori Ohdaira, Nobuhiro Tsutsui, Norihiko Suzuki, Eisaku Ito, Keigo Nakajima, Satoru Yanagisawa, Masaki Kitajima, Yutaka Suzuki, A case of incarcerated femoral hernia with intestinal blood flow assessment by brightfield full-color near-infrared fluorescence camera: Report of a case, *International Journal of Surgery Case Reports*, Volume 29, 2016, Pages 234-

Open Access This article is licensed under a Creative Commons Attribution 4.0 International License, which permits use, sharing,



adaptation, distribution and reproduction in any medium or format, as long as you give appropriate credit to the original author(s) and the source, provide a link to the Creative Commons license, and indicate if changes were made. The images or other third party material in this article are included in the article's Creative Commons license, unless indicated otherwise in a credit line to the material. If material is not included in the article's Creative Commons license and your intended use is not permitted by statutory regulation or exceeds the permitted use, you will need to obtain permission directly from the copyright holder. To view a copy of this license, visit <http://creativecommons.org/licenses/by/4.0/>.

© The Author(s) 2024