

A Study on Trends of Chest X-Ray Radiological Patterns in Community Acquired Pneumonia, In Association with Bacterial and Fungal Etiologic Agents

Dr. A. V. Sowmya ^{*1}, Dr. David Agatha ², Dr. G. Jayalakshmi ³

¹Associate Professor of Microbiology, Govt. Stanley Medical College, Chennai, Tamil Nadu, India.

²Professor of Microbiology, Madras Medical College, Chennai, Tamil Nadu, India.

³Retired Director, Institute of Microbiology, Madras Medical College, Chennai, Tamil Nadu, India.

*Corresponding Author: Dr. A.V. Sowmya; sowm78@gmail.com

Received: 06 February 2025;

Revised: 03 March 2025;

Accepted: 13 March 2025;

Published: 20 March 2024

Abstract

Introduction: Pneumonia is one of the leading cause of infectious disease worldwide. Chest radiography plays a crucial role in clinical diagnosis of Community Acquired Pneumonia (CAP). This study is conducted to identify the common infiltrative patterns in CAP and their association with specific microbial pathogens. **Materials & Methods:** Chest radiography infiltrative patterns for about 150 cases of CAP are studied and the specific etiologic pathogens were identified by microbiological investigations, according to Standard Operating Procedures. **Results:** The most common type of radiologic finding is lobar type of consolidation (55.33%) followed by bronchopneumonia type of consolidation (17.33%). Culture positivity rate was 69.33%. Monomicrobial infection was identified in 90 cases (86.54%), while polymicrobial infection was found in 14 cases (13.46%). Bacterial pathogens predominate over fungal pathogens. 85.18% of *K. pneumoniae* isolates presented with lobar type of consolidation. 66.66% of *Staphylococcus aureus* isolates with bronchopneumonia type of consolidation. 50-100% of poly microbial infections presented with lobar type of consolidation. 27.77 % each of fungal isolates presented with cavitary consolidation and nodular type of consolidation. **Conclusion:** As newer pathogens are emerging with specific pattern of chest infiltrates, primary knowledge about the specific chest X ray patterns by various pathogens are important to obtain preliminary idea about the possible pathogen and thereby to choose an ideal empiric antibiotic therapy, which is the main line of treatment in CAP.

Keywords: *Community Acquired Pneumonia, Chest X ray, infiltrative patterns, etiologic agents.*

Introduction

Community Acquired Pneumonia (CAP) is a major cause of infectious public health problem throughout the world, with high morbidity and mortality rate. Admission rates in hospitals, due to pneumonia vary between 22-51% worldwide, the mortality rate being higher in developing and under developed countries ^[1]. In addition to patient care costs, even in young healthy adults, pneumonia is responsible for over 50 million days of restricted activity from work and is the sixth leading cause of death ^[2].

CAP is caused by a wide spectrum of microorganisms and newer pathogens are constantly identified and included in the list. The host responses are also altered by newer techniques of interventions, medications and other co-existing diseases. Imaging plays a crucial role and plain chest radiography is an inexpensive and an important initial investigation in all cases of suspected pulmonary infections. According to American Thoracic Society guidelines, posteroanterior (PA) (and lateral when possible) chest radiography should be obtained whenever pneumonia is suspected

in adults ^[3]. Chest radiograph (x-ray) is recommended in all suspected pneumonia cases, as their primary role is to support a clinical diagnosis of pneumonia, provide a preliminary idea about the underlying pathogen, guiding in formulating empirical therapy and also in identifying complications.

Varied pathogens of CAP produce rather specific radiographic findings, thereby the diagnosis of infectious pathogen can be very well narrowed down and a differential diagnosis can be made. Majority of pulmonary infiltrates in CAP develop within 12 hrs. A specific pattern of involvement can suggest a likely diagnosis in many instances. A combination of pattern recognition with knowledge of the clinical setting is the best approach to the pulmonary infectious processes.

Not much studies are available in identifying the specific radiologic patterns of chest radiography in association with the microbial pathogens. This study is conducted to understand the varied radiographic findings noted in cases of CAP and the possible imaging patterns produced by various bacterial and fungal agents causing CAP, in a tertiary care hospital setup.

Materials and Methods

The study was conducted in a tertiary care hospital for period of one year, after getting Institutional Ethical Committee approval. Patients who were admitted in various wards of the hospital with presenting signs and symptoms of high-grade fever, chills and rigors, cough with sputum production, dyspnea, tachycardia, tachypnea, focal signs in physical examination and chest radiography infiltrates were included in the study group. A total of 150 in-patients were included in the study group and informed consent was obtained from them. Data were collected from patients who satisfied the inclusion criteria, using preformed structured questionnaire. Demographic details like name, age sex, address, date of admission, clinical details like presenting complaints, personal history, past medical history, history suggestive of associated immunocompromised state, chest radiographic findings, physical examination findings and details of clinical diagnosis were collected. The chest radiographs were analysed by radiologists who gave their opinion regarding the type of infiltrates.

Various respiratory samples (sputum, induced sputum, bronchoalveolar lavage-BAL fluid) were collected under strict aseptic precautions in sterile containers, properly labelled and were transported to the laboratory in appropriate condition as soon as possible. The samples were processed and etiologic pathogens were isolated, identified and their antimicrobial susceptibility pattern were obtained as per Standard Operating Procedures. The results were documented and analysed statistically.

Results

A total of 150 patients were included in the study group, during the one-year study period. Majority of the patients were males (66.67%), belonging to the age group of 41-70 yrs (56.67%).

Table 1: Associated chest X ray findings(n=150)

Sl.no.	X ray finding	No.	%
1.	Lobar consolidation	83	55.33
2.	Broncho pneumonia	26	17.33
3.	Interstitial pneumonia	11	7.33
4.	Multilobar pneumonia	8	5.33
5.	Cavitary consolidation	7	4.67
6.	Necrotizing pneumonia	6	4
7.	Nodular pneumonia	5	3.33
8.	Multilobar necrotising	2	1.33
9.	Multi nodular	1	0.67
10.	Perihilar infiltrates	1	0.67

The most common type of radiologic finding is lobar type of consolidation (55.33%), followed by bronchopneumonia type of consolidation (17.33%) (Table 1).

Of the 150 respiratory samples analysed, a total of 104 pathogens were isolated and identified, with culture positivity rate being 69.33%. Monicrobial infection was identified in 90 cases (86.54%), while polymicrobial infection was found in 14 cases (13.46%). Bacterial pathogens predominate over fungal pathogens, with significant P value (0.031)

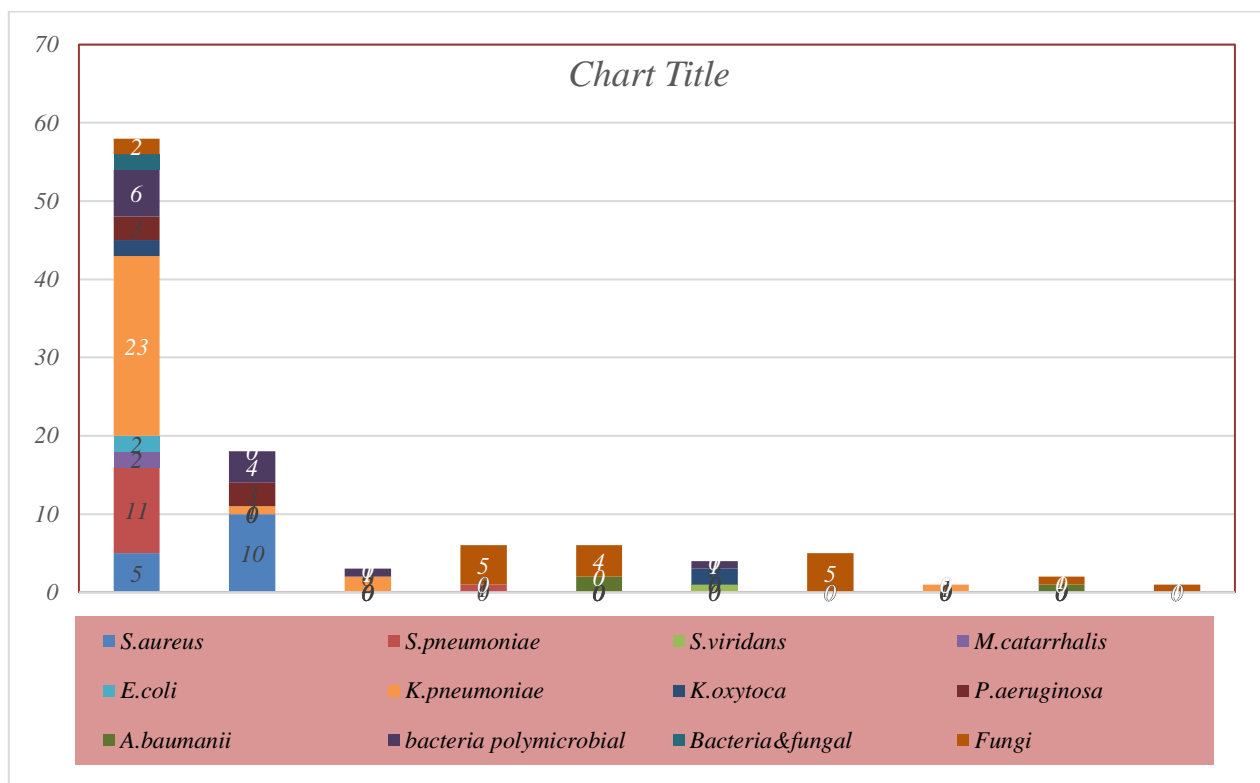


Figure 2: Correlation of isolates from respiratory samples with chest X ray –type of infiltrates

85.18% of *K. pneumoniae* isolates presented with lobar type of consolidation.

66.66% of *Staphylococcus aureus* isolates presented with bronchopneumonia type of consolidation.

91.66% of *Streptococcus pneumoniae* isolates presented with lobar type of consolidation.

50-100% of poly microbial infections presented with lobar type of consolidation

27.77 % each of fungal isolates presented with cavitary consolidation and nodular type of consolidation (Figure 1).

Discussion

Despite advances in diagnostic modalities, Pneumonia is one of the major infectious disease where diagnosis needs a combination of clinical intellect with laboratory diagnostic aids. Though Microbiological analysis can give definitive diagnosis with guidelines to select appropriate antibiotics, initial plain Chest radiograph may help to confirm the presence of infiltrates compatible with CAP and also to exclude other pulmonary conditions that may clinically mimic CAP.

This study is conducted in a tertiary care hospital to identify the common radiographic patterns of consolidation noted in CAP and also to correlate the chest infiltrates type with associated pathogen. Over a one-year study period, about 150 consecutive patients presented with signs & symptoms of CAP were included in the study and their chest X ray infiltrative patterns were analysed.

In the current study the most common radiologic finding in chest X ray is lobar consolidation (55.33%), followed by bronchopneumonia (17.33%). Several such studies like the ones conducted by Subhakar Kandi *et al.* [4], T. Franquet *et al.* [5] and JH Reynolds *et al.* [6] on aiming at imaging trends & diagnosis of CAP, found that lobar type of consolidation is the most common type of radiologic infiltrate in CAP, closely followed by bronchopneumonia. This is due to the fact that the most common etiologic agents of CAP is bacterial which usually presents as lobar pneumonia, especially *Streptococcus pneumoniae* and *Klebsiella pneumoniae*.

In studying the association of bacterial isolates with the radiologic findings, about 85.18% of *K. pneumoniae* isolates, 91.66% of *S. pneumoniae* isolates and 50-100% of poly microbial infections, presented with lobar type of consolidation in radiologic pictures. Studies conducted by JH Reynolds *et al.* [6], Tarver R *et al.* [7] and Sharma S *et al.* [8] had showed that most common radiological pattern of pneumonia caused by *S. pneumoniae* and Enterobacteriaceae isolates like *E. coli*, *K. pneumoniae* is lobar type of consolidation. The study also showed that *S. aureus* and *P. aeruginosa* isolates commonly presents as lobular(bronchopneumonia) type of consolidation, the finding being similar to our study where 66.66% of *Staphylococcus aureus* isolates presented with lobular type of consolidation.

The major type of radiologic finding which is found in association with fungal isolates is cavity with consolidation & nodular type of consolidation (27.77%, each), followed by multilobar consolidation (22.22%). Authors Collins *et al* [9] had identified that invasive aspergillosis most commonly presents as nodular infiltrates, cavity with consolidation and multifocal infiltrates. Study by Albelda *et al* [10] showed that fungal pneumonia in leukaemia patients commonly presents as nodular infiltrates with cavitation.

Nearly all cases of polymicrobial infection have produced lobar type of consolidation, which is of course the common type of infiltration pattern in CAP. Not many studies are there which evaluate the chest X ray infiltration pattern in polymicrobial type of CAP. Our study indicates that careful microbiological evaluation is necessary in cases of lobar pneumonia to identify polymicrobial infections. As indicated in various studies, the usual pattern of chest X ray in CAP is lobar pneumonia, but our study reveals that the radiographic patterns are often variable and they are often related to the causative agent.

Conclusion

Pneumonia is a common and potentially lethal infectious disease for nearly two centuries. As the pathogens associated with CAP has

become varied and diversified, since the onset of HIV and COVID-19 pandemic era, advancements in treatment methodology and of course the changing resistance patterns of common pathogens, the common old knowledge of CAP association with lobar consolidation is just not enough in diagnosis and management.

Radiology is a cost effective, simple, initial screening and diagnostic tool in CAP. Pattern recognition may help to identify the potential pathogen in a given patient, favouring a bacterial over viral pathology. As the outcome in CAP is improved by early recognition and rapid institution of empirical antibiotic therapy, current knowledge in the varied radiology patterns exhibited by the microorganisms is necessary and play an important role in formulating empirical antibiotic therapy. Also pattern recognition may give an idea about the underlying preexisting risk factor in patients, which helps in their proper management.

Diagnosis and proper management of pneumonia depends on combination of clinical awareness, proper and regular microbiology studies and radiographical studies.

Declarations

Ethical Approval

Approved by Institutional ethical Committee

Conflict of Interest

Nil

Funding Statement

Self-funding

Data Availability

Available on corresponding author upon responsible request.

Author's Contribution

Dr. A.V. Sowmya: Literature survey, Concept, Design, Implementation of study protocol, defining intellectual content, processing, report generation, data analysis and interpretation, manuscript preparation and revision.

Dr. David Agatha: Concept, Design, defining intellectual content, data analysis and interpretation, coordination in manuscript preparation and revision.

Dr. G. Jayalakshmi: Concept, Design, defining intellectual content, defining study protocol, interpretation and manuscript revision.

Acknowledgment

We sincerely thank the faculty of Institute of Radiology, Madras Medical College for the support rendered by them.

We sincerely thank, Mr. M. Yuvan Viswanathan, second year MBBS student, Government Medical College, Tiruvallur, for participating in the technical editing of this manuscript.

References

- [1] Okinen C, Heiskanen L, Juvonen H, *et al.* Incidence of community-acquired pneumonia in the population of four municipalities in eastern Finland. *Am J Epidemiol* 1993; 137:977-988.

- [2] Garibaldi RA. Epidemiology of community-acquired respiratory tract infections in adults: incidence, etiology, and impact. *Am J Med* 1985;78: Suppl. 6B, 32-37.
- [3] Boiselle PM, Crans CA Jr, Kaplan MA. The changing face of *Pneumocystis carinii* pneumonia in AIDS patients. *AJR* 1999; 172:1301-1309.
- [4] Subhakar Kandi. Diagnosis of Community Acquired Pneumonia. Supplement to JAPI; January 2012; Vol. 60: 17-20.
- [5] Franquet. T. Imaging of pneumonia: trends and algorithms. *European Respiratory Journal*. July 1, 2001; vol. 18; no. 1:196-208.
- [6] J H Reynolds, G McDonald, H Alton, and S B Gordon. Pneumonia in the immunocompetent patient. *Br J Radiol*. 2010. December; 83(996): 998–1009.
- [7] Traver R, Teague S, Heit Kamp D, Conces D. Jr Radiology of community acquired pneumonia. *Radiol Clin North Am*; 2005; 43:497-512.
- [8] Sharma S, Maycher B, Eschun G. Radiological Imaging in Pneumonia: Recent Innovations: Imaging of Bacterial Pneumonia. *Curr Opinion on Pulmo*.2007 May;13(3):159-69.
- [9] Collins, Jannette; Stern, Eric J. Upper Lung Disease, Infection, and Immunity. *Chest Radiology: The Essentials*, 2nd Edition. Chapter 10.pg:177-179.
- [10] Albelda SM, Talbot GH, Gerson SL, *et al.* Pulmonary cavitation and massive haemoptysis in invasive pulmonary aspergillosis: influence on bone marrow recovery in patients with acute leukaemia. *Am Rev Respir Dis*.1985; 131:115-120.



Open Access This article is licensed under a Creative Commons Attribution 4.0 International License, which permits use, sharing, adaptation, distribution and reproduction in any medium or format, as long as you give appropriate credit to the original author(s) and the source, provide a link to the Creative Commons license, and indicate if changes were made. The images or other third party material in this article are included in the article's Creative Commons license, unless indicated otherwise in a credit line to the material. If material is not included in the article's Creative Commons license and your intended use is not permitted by statutory regulation or exceeds the permitted use, you will need to obtain permission directly from the copyright holder. To view a copy of this license, visit <http://creativecommons.org/licenses/by/4.0/>.

© The Author(s) 2025